

Occult Secondary Lesion

West Valley Imaging - Las Vegas, NV

Breast-Specific Gamma Imaging with the Dilon 6800

Clinical History

82 year-old female with moderate quantity of bilateral stable dense breast parenchyma.

Mammogram

New nodular density with spiculation noted in spot compression. BIRADS 4.

Ultrasound

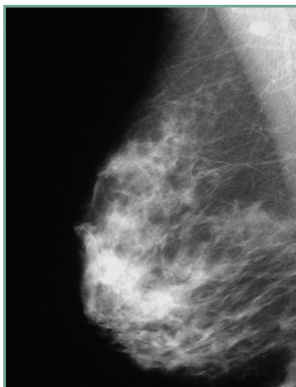
No cysts or solid masses noted.

Breast-Specific Gamma Imaging

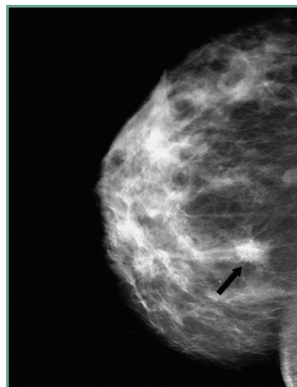
Two foci of significant uptake noted. The first is consistent with the nodular density noted in the mammogram. The second is within the area of stable dense breast parenchyma.

Histopathology Findings

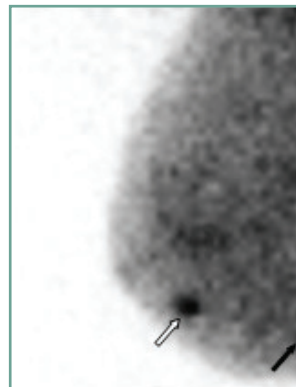
Infiltrating ductal carcinoma findings in both sites.



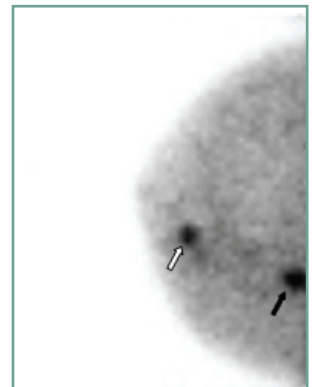
RMLO mammogram



RCC mammogram



RMLO BSGI



RCC BSGI

BSGI detected a second site of carcinoma not indicated in other modalities, thereby dramatically changing the course of treatment in this case.

