

Implants

George Washington University Medical Center - Washington, D.C.

Breast-Specific Gamma Imaging with the Dilon 6800

Clinical History

49 year-old; had a left breast biopsy in 1998 that reported hyperplasia. Has had saline implants since 1995 and mother had breast cancer.

Mammogram

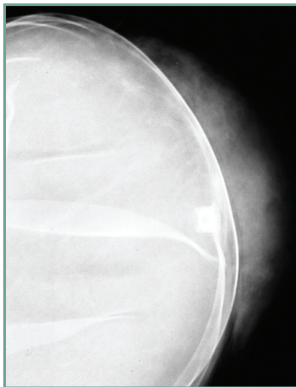
Mammograms difficult to interpret due to implant radiodensity; saline implants in good condition. BIRADS 1.

Breast-Specific Gamma Imaging

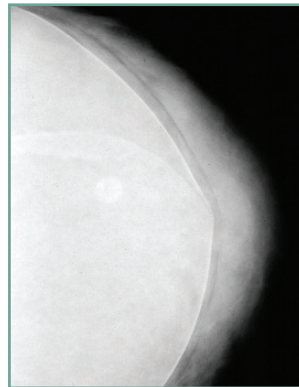
Good visualization of soft tissue radio tracer distribution without foci or high intensity. NORMAL.

Histopathology Findings


Biopsy not indicated.



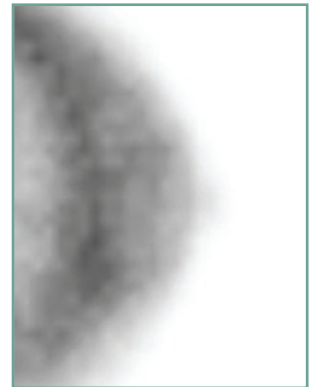
LML0 mammogram



LCC mammogram



LML0 BSGI



LCC BSGI

