

Indeterminate Mammogram with Positive BSGI

George Washington University Medical Center - Washington, D.C.

Breast-Specific Gamma Imaging with the Dilon 6800

Clinical History

Postmenopausal patient with bilateral palpable masses; no prior mammograms.

Mammogram

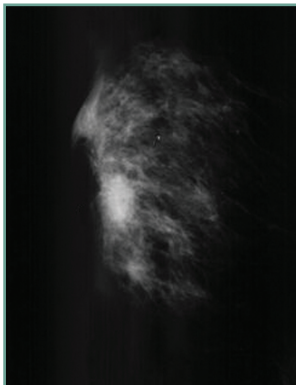
Right breast: shows an area of asymmetry, dissipating with spot compression, determined to be benign fibroglandular tissue.

Breast-Specific Gamma Imaging

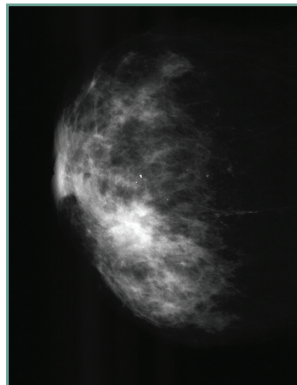
Three large foci of high intensity extending from nipple-line toward the superior posterior margin from the 9 o'clock position. The center focal uptake is large and spatially correlated with mass found in mammogram. POSITIVE.

Histopathology Findings

Three lesions of infiltrating mammary carcinoma with ductal and lobular cell types.




RMLO mammogram



RCC mammogram



RMLO BSGI



RCC BSGI

