

# Radiodense Mammogram with True Negative BSGI

West Valley Imaging - Las Vegas, NV

## Breast-Specific Gamma Imaging with the Dilon 6800

### Clinical History

In 1969, patient underwent silicone injections. After three sessions, patient increased one full cup size.

### Mammogram

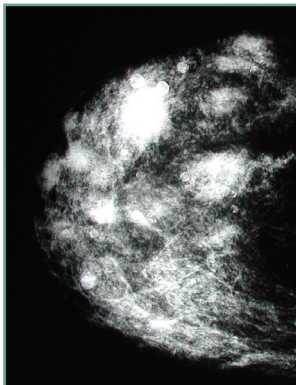
Right breast mammogram difficult to interpret due to very dense silicone globulomas obscuring visualization of the breast tissue. BIRADS 2.

### Breast-Specific Gamma Imaging

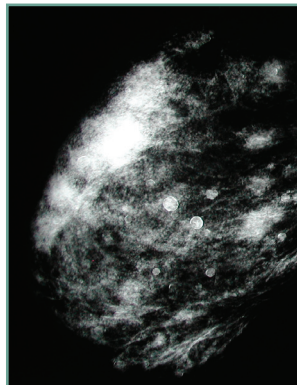
No focus or region of increased uptake. Normal uniform distribution. NORMAL.

### Histopathology Findings


No biopsy required. A follow-up mammogram recommended after 12 months. Negative.



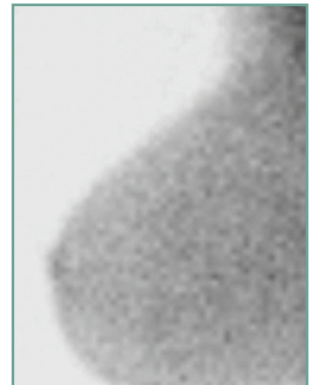
RCC mammogram



RML0 mammogram



RCC BSGI



RML0 BSGI

BSGI is a useful tool to find disease in patients with Radiodense breasts.

