

# DCIS

West Valley Imaging - Las Vegas, NV

## Breast-Specific Gamma Imaging with the Dilon 6800

### Clinical History

82 year-old female with a history of multiple nodules in the left breast.

### Mammogram

Symmetric density which, under spot compression, demonstrates a 1.4 cm x 1.0 cm microlobulated mass with spiculation of its margins.

### Ultrasound

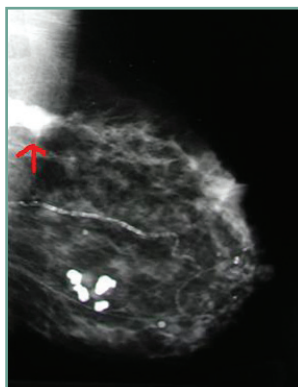
Multiple nodules with a larger, central 1.2 cm x 1.0 cm hypoechoic mass.

### Breast-Specific Gamma Imaging

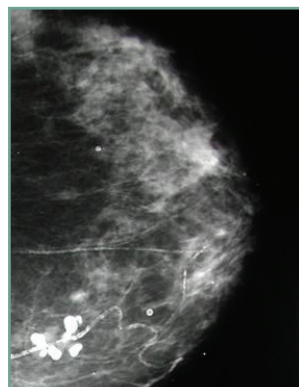
Area of significant uptake corresponding to the mammographic density. Suggestive of malignant process.

### Histopathology Findings

1 cm ductal carcinoma in situ.



LMLO mammogram



LCC mammogram



LMLO BSGI



LCC BSGI

BSGI provides high sensitivity and specificity for sub-centimeter carcinomas, including DCIS.



Dilon Technologies LLC

12050 Jefferson Avenue; Newport News, VA 23606

Phone: 757.269.4910; Fax: 757.269.4912; www.dilon.com

